











Temporomandibular joint articular disc position and shape in skeletal Class III

Daniella Torres Tagawa^{1,2}  | Alexandre de Albuquerque Franco³  | Andrea Puchnick¹  |
Angela Maria Borri Wolosker¹  | Bruna Maluza Florez²  | Gladys Cristina Dominguez⁴  |
Helio Kiitiro Yamashita¹  | Lucia Helena Soares Cevidanes⁵  |
Luis Antonio de Arruda Aidar²  | Henrique Carrete Junior¹ 

¹Department of Diagnostic Imaging, Escola Paulista de Medicina, Universidade Federal de São Paulo, São Paulo, Brazil

²Department of Orthodontics, Universidade Santa Cecília, Santos, Brazil

³Private Practice, Aracaju, Brazil

⁴Department of Orthodontics, Universidade de São Paulo (USP), São Paulo, Brazil

⁵Department of Orthodontics and Pediatric Dentistry, School of Dentistry, University of Michigan, Ann Arbor, Michigan, USA

Correspondence

Daniella Torres Tagawa, Department of Diagnostic Imaging, Escola Paulista de Medicina, Universidade Federal de São Paulo, Rua Napoleão de Barros 800, São Paulo, SP 04024-002, Brazil.
Email: daniellatorres79@hotmail.com

Funding information

Coordenação de Aperfeiçoamento de Pessoal de Nível Superior

Abstract

Objective: To compare the position and shape of the temporomandibular joint (TMJ) articular disc among the sagittal and vertical skeletal patterns in Angle Class III, Class III subdivision malocclusion and normal occlusion. The null hypothesis was that there was no difference in disc position and shape in different (1) malocclusions and (2) skeletal patterns.

Methods: This cross-sectional observational study evaluated 105 patients divided into 3 groups: Class III (33, 9.39 ± 1.96 years), Class III subdivision (45, 9.51 ± 1.59 years) and a normal occlusion (27, 10.24 ± 0.87 years) was included as healthy control. Severity of the maxilla-mandibular anteroposterior discrepancy and vertical facial pattern were determined using 2D cephalometry, and the position and shape of the articular discs were evaluated in magnetic resonance images. Statistical parametric and non-parametric tests and Kappa analysis for intra-observer and inter-observer assessment were used ($p \leq .05$).

Results: Significant between-group differences were found in articular disc position. In the normal occlusion group, all the articular discs were well positioned. In Class III and Class III subdivision, the discs were displaced in 30.3% and 12.2% of the TMJs, respectively. Sagittal and vertical skeletal patterns did not affect the findings significantly. The Class III subdivision malocclusion group is probably different from the other groups, showing 97.7% of biconcave discs in both TMJs.

Conclusion: The longitudinal follow-up of this sample becomes relevant as the two groups with malocclusion in the pre-peak phase of pubertal growth showed differences in the prevalence of displacement and form of the articular disc, with no association with their vertical facial characteristics.

KEYWORDS

Angle Class III, diagnosis, magnetic resonance imaging, malocclusion, temporomandibular joint, temporomandibular joint disorders

1 | INTRODUCTION

Class III malocclusion is defined as an anteroposterior discrepancy with skeletal, dental or functional involvement. Skeletal Class III malocclusion can occur because of deficient maxillary growth (most prevalent), excessive mandibular growth or a combination of both.¹

The literature has shown correlation between temporomandibular disorders (TMDs) and dentofacial deformities. However, the prevalence of TMD in these patients is still controversial.^{2,3} Understanding the amount and direction of condylar growth and development, and classifying the facial pattern are important not only for the orthodontic diagnosis and treatment of TMD but also to formulate preventive measures against these disorders.⁴ The literature presents few studies correlating the degree of sagittal and vertical skeletal discrepancy associated with Angle Class III malocclusion with possible changes in the temporomandibular joint (TMJ) status.⁵

A study reported signs and symptoms of joint dysfunction in 35% of the patients with mandibular prognathism, and among those with asymmetry associated with prognathism, 58% had disc displacement.⁶ Therefore, skeletal morphology could also be considered a possible risk factor for the development of disc displacement.⁷

Regarding diagnostic means, magnetic resonance imaging (MRI) has advantages compared to arthrography and CT as it is a non-invasive method that does not require ionizing radiation for image acquisition and allows direct visualization of disc and joint structures.⁸⁻¹⁰

A prospective clinical study evaluated the effect of Fränkel Functional Regulator-II treatment in Class II subjects in the pre-peak phase of puberty concluded that there was low prevalence of disc displacement and biconcave-shaped disc.¹¹

There are few studies in the literature evaluating the position and shape of the TMJ articular disc in patients with Class III malocclusion using MRI.¹²⁻¹⁴ Disc displacement could be associated with changes in mandibular growth.¹⁵ However, prospective and longitudinal studies are necessary to corroborate these findings.¹⁶ Furthermore, conventional treatments, such as reverse maxillary protraction with or without mini-implants and chin cups, impact the TMJ.¹⁴ Therefore, knowing the TMJ status, through physical examination and, eventually, by imaging tests, may provide information for diagnosis and treatment planning.

The objective of this study was to compare the position and shape of the TMJ articular disc among the sagittal and vertical skeletal patterns in Angle Class III, Class III subdivision malocclusion and normal occlusion. The null hypothesis was that there was no difference in disc position and shape in different (1) malocclusions and (2) skeletal patterns.

2 | MATERIAL AND METHODS

This study was approved by the Ethics Committees of the Universidade Santa Cecília, Santos, Brazil and Escola Paulista de Medicina, UNIFESP, São Paulo, Brazil (protocols numbers

32453714.5.0000.5513 and 79580417.4.0000.5505). Patients participated in the study after they and their parents signed informed consent and assent forms, respectively, agreeing with all stages of the study and the subsequent publication of results.

This cross-sectional observational study included patients with Angle Class III, Class III subdivision malocclusions and normal occlusion. Seventy-eight patients were consecutively selected at the Department of Orthodontics, Universidade Santa Cecília, Brazil, and divided into two groups: Class III (33, 14 boys and 19 girls, mean age at 9.39 ± 1.96 years, ranging from 6.08 to 14.08 years) and cervical vertebral maturation stage (CVMS)¹⁷ – 21 cases CVMS I and 12 CVMS II and Class III subdivision (45, 17 boys and 28 girls, mean age at 9.51 ± 1.59 years, ranging from 6.66 to 13.50 years) – 32 cases CVMS I and 13 CVMS II.

Inclusion criteria: (1) patients with anteroposterior maxillomandibular discrepancy caused by maxillary retrusion (open nasolabial angle), mandibular protrusion (chin-neck line augmented and normal chin-neck angle) or a combination of both, clinically evaluated by facial analysis; (2) Angle Class III or Class III subdivision malocclusion; (3) mixed dentition or beginning of permanent dentition, with and without posterior crossbite. The Class III malocclusion group had mean AO-BO- 8.02 ± 2.29 mm (ranging from -14 to -4 mm), and the Class III subdivision group had mean AO-BO- 5.71 ± 2.38 mm (ranging from -11 to -2 mm).

Exclusion criteria: (1) patients with decayed teeth, (2) previous orthodontic treatment, (3) presence of a metallic device, claustrophobia or anxiety that would prevent them from having the MRI examination.

Orthodontic records from twenty-seven patients (10 boys and 17 girls) with normal occlusion, with mean age of 10.24 ± 0.87 years, ranging from 8.80 to 11.90 years – 10 cases CVMS I and 17 CVMS II, are available at the Department of Orthodontics, Universidade Metodista de São Paulo, Brazil, and were recruited observing the following clinical aspects: with molar relationship of Class I or edge-to-edge, and canines in Class I, with overjet ranging from 1 to 2.5 mm, passive lip seal and without crowding.¹⁸ The normal occlusion group had mean AO-BO- 0.65 ± 1.51 mm (ranging from -5 to 2.5 mm).

Five calibrated examiners took part in the research: two trained orthodontists were calibrated with material from other patients (extraoral photographs and cephalometric tracing) before the evaluation of the said sample (selection, clinical examination of patients and cephalometric tracing), two radiologists (MRI evaluation) and one TMD specialist (classification of malocclusion using Dawson's bimanual technique).¹⁹

Anamnesis, dental clinical examination, dynamic and muscular TMJ palpation (anterior, middle and posterior temporal; origin, insertion and body of the superficial masseter; deep masseter; posterior digastric; sternocleidomastoid, upper trapezius) and measurement of the degree of maximum opening were performed.

Centric relation (CR) defines the condition of the condyle-disc assemblies. A professional trained in Dawson's bimanual technique¹⁹ evaluated the entire Class III sample to avoid the risk of including pseudo-Class III patients. CR was successfully achieved with gentle

manipulation, firmly holding the seated condylar axis, uppermost position when marking the occlusal contact. The stages were as follows: (1) Recline the patient so his arms are parallel to the floor, (2) Point the patient chin up, (3) Stabilize the head, (4) Gently position the four fingers of each hand on the lower border of the mandible, (5) Bring the thumbs together to form a 'C'. The CR recording was verified by load testing as accurate. It was possible to fully load the joints with no response after adding the compression of the joints in three increments. According to the Dawson technique, this manoeuvre is considered essential to certify a reliable centric position. In some cases, the sample had small discrepancies between the CR and centric occlusion (CO) of less than 2.5 mm. This finding did not justify their exclusion of the sample, as it did not modify the Class III condition determined by the other parameters used on at least one side of the molar relationship. Thus, MRI examination was considered as the only criterion to perform TMJ evaluation in all participants in the sample, with the interarch relationship in the CO maxillomandibular position.

Digital lateral cephalometric telerradiographs were obtained on the same cephalostat using the Orthophos XG X-ray machine (Sirona Dental, Bensheim, Germany) in right lateral norm and CO. Cephalograms were drawn on acetate sheets by two observers trained in the method. The cephalometric variables were measured with a protractor and a millimetre ruler with 0.5° and 0.5 mm, respectively, and included the Wits analysis (AO-BO)²⁰ and the facial pattern (Ricketts' VERT)²¹ (Figure 1).

The patients underwent MRI examinations of both TMJs at the Department of Diagnostic Imaging, Hospital Guilherme Álvaro, Santos, Brazil, following the safety criteria of the method (Before examination, patients answered a questionnaire. In the presence of screws or metallic plates in the body, the procedure was contraindicated).

TMJ MRI was obtained using a superconducting 1.5-Tesla scanner (Philips Achieva, Eindhoven, Netherlands) with bilateral surface coils. All scans were performed on the same equipment, with the same protocols and recorded in the Digital Imaging and Communication in Medicine format. The images were evaluated using the OsiriX software.

The examinations were conducted according to the following protocol and sequences: 18 cuts (nine for each TMJ) documented with a 2.0 magnification. Planning was sagittal oblique, which is perpendicular to the axis of the head/mandibular condyle in the axial plane and follows sagittal orientation in the coronal plane of the condyle/mandibular ramus.⁸

The MRIs were performed by using T1-weighted (T1-w) axial planning images; T1 TSE sagittal oblique images with closed and open mouth (OM) (TR/TE, 2000/30; FOV, 18 cm; matrix, 512 × 512); T2 TSE sagittal oblique images with closed and OM (TR/TE, 3000/30/60; FOV, 18 cm; matrix, 512 × 512); proton density TSE sagittal oblique images with closed and OM (TR/TE, 2000/30; FOV, 18 cm; matrix, 512 × 512) and proton density TSE coronal images (TR/TE, 2000/30; FOV, 20/23 cm; matrix, 512 × 512). In all images, the thickness/increment was 2.5/1.0 0.6 mm.

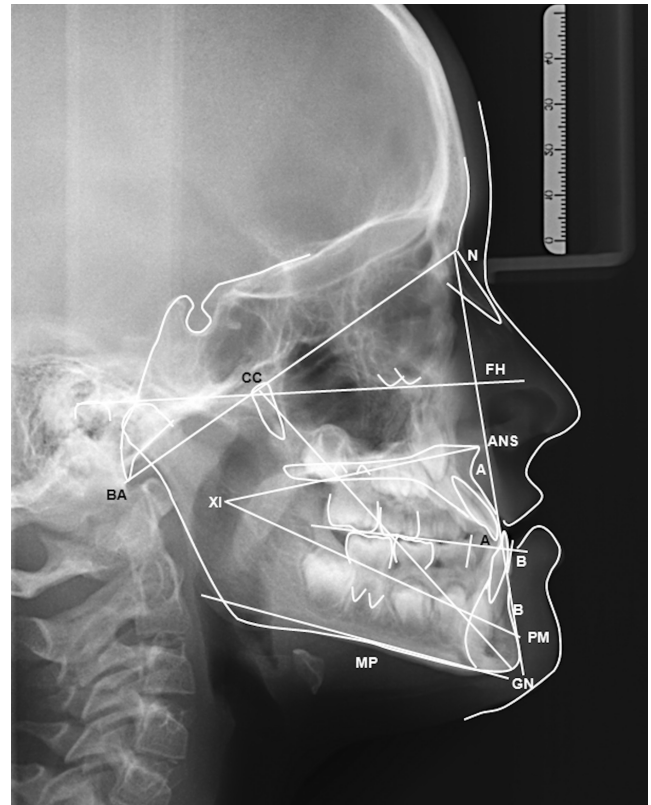


FIGURE 1 Cephalometric tracing: Wits - AO-BO²⁰ and Ricketts' VERT.²¹ Wits appraisal: Perpendicular lines dropped from point A to point B onto occlusal plane. 'Wits' reading was measured from AO to BO. Ricketts analysis: The cephalometric measurements were facial axis angle, BA-CC-GN; facial depth angle, crossing of facial plane to FH; mandibular plane angle, crossing of mandibular plane to FH; lower facial height angle, ANS-XI-PM; mandibular arc angle, crossing of condylar axis to corpus axis. Ricketts's VERT was obtained from an average measurement of five factors found by the difference between the measured value and the individual standard divided by the standard deviation (which varies with the angle). A positive sign was assigned when the value indicated a trend of brachyfacial growth, and a negative sign was assigned when the value found indicated a dolichofacial trend, and intermediate type named mesofacial.

MRI was performed in the closed mouth (CM) position with the teeth at maximum habitual intercuspation. In the OM position, wooden toothpick blocks were interposed between the anterior teeth to keep the mouth open in the maximum comfortable position, with interincisal measurement during the pre-established clinical evaluation of each patient.

MRI scans were interpreted by two experienced and trained radiologists in a double-blind manner, without one observer being aware of the other's interpretations, following the established protocols.^{9,22,23} Observer 1 (O1) performed two evaluations at different times, and observer 2 (O2) performed only a single evaluation. In case there was no agreement on the diagnosis, the observers reached a consensus through discussion.

Qualitative evaluations of the position and shape of the articular disc were performed for the left and right TMJs in CM⁹ and OM¹⁰

positions. The coronal plane was used to assist the diagnosis of articular disc position in the lateromedial direction^{9,10} (Figure 2A–F). Disc shape was biconcave, non-biconcave, or undetermined (disc not visualized).²³

2.1 | Statistical analysis

Sample radiographs (20%) were selected at random. All radiographs were traced and measured again by two observers. With the two measurements, at different times from observer 1 (O1a and O1b), intra-observer agreement was evaluated. With the second measurement of observer 1 (O1b) and the measurements of observer 2 (O2), inter-observer agreement was performed. Both the absolute technical error of measurement (TEM) and relative technical error of measurement (rTEM) were calculated, considering rTEM values below 1.0% and 1.5% (experienced observers) in the intra-observer and inter-observer analysis, respectively. Systematic error was evaluated using Student's *t* test for paired samples, while random error was assessed by calculating the intraclass correlation coefficient (ICC). Finally, the reliability coefficient (RC) was calculated.

Absolute (number) and relative (%) frequencies were presented for TMJ variables on MRI. The McNemar test was used to verify whether there was a difference between the right and left sides of the TMJ. In all comparisons, the *p*-value was not significant between the two sides. Therefore, we considered a total sample of 156 TMJs regardless of the side.

The Kappa statistic (κ)²⁴ was used to analyse the agreement between O1 and O2 evaluations and the 95% confidence interval O1 evaluations at different times were considered for intra-observer agreement analysis. The second O1 and O2 evaluations were used for inter-observer agreement analysis. When there was a disagreement on TMJ diagnosis, the observers reached a consensus through discussion.

Unweighted Kappa values were considered for square (2×2) tables, and Kappa tables with linear or quadratic weighting were used in cases where it was not possible to build 2×2 tables. The parameters used in the strength of the Kappa test agreement were as follows: $\kappa < 0.000$ (equivalent to chance), $\kappa = 0.000–0.200$ (slight), $\kappa = 0.210–0.400$ (fair), $\kappa = 0.410–0.600$ (moderate), $\kappa = 0.610–0.800$ (substantial) and $\kappa = 0.810–1.000$ (near perfect/perfect). When it was not possible to calculate the Kappa value,

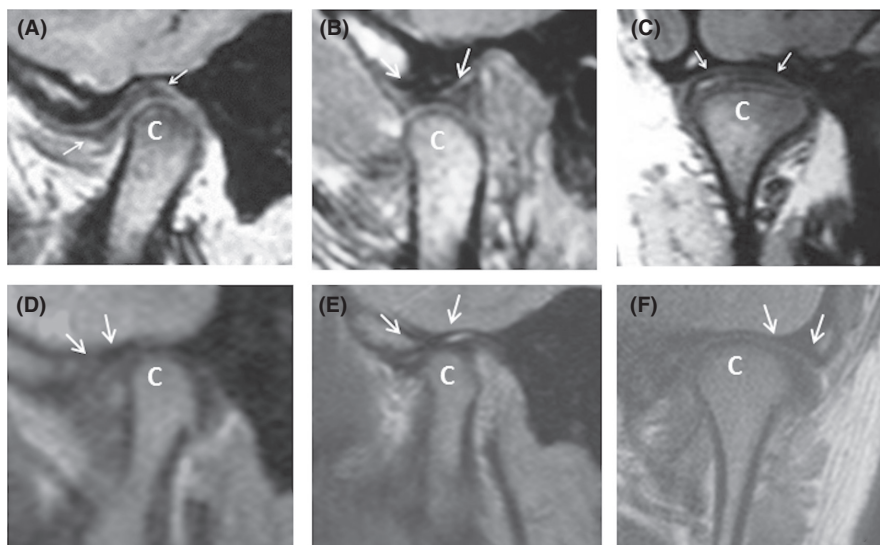


FIGURE 2 A, Articular disc position and shape in CM position: normal position and biconcave shape. B, Articular disc position in OM position: intermediate zone of disc (arrow) interposed between condyle (C) and articular tubercle. C, Articular disc position in coronal plane: normal position. D, Anterolateral displacement in CM position and non-biconcave shape. E, Reduction of disc, placed between condyle and articular tubercle in OM position. F, Articular disc position in coronal plane: lateral. Classification criteria from Tasaki et al.⁹ Normal disc position (posterior band of disc superior to condyle or central thin zone [intermediate zone] of disc located between anterior prominence of condyle and posterior aspect of articular eminence); Anterior (ADD – Posterior band of disc anterior to anterior prominence of condyle throughout mediolateral dimension of joint); Partial anterolateral (Disc anteriorly displaced in lateral part of joint and disc in superior position in medial part of joint with no sideways component to displacement); Partial anteromedial (Disc anteriorly displaced in medial part of joint and in superior position in lateral part of joint with no sideways component to displacement), Anterolateral (ALDD – Disc anteriorly and laterally displaced); Anteromedial (AMDD – Disc anteriorly and medially displaced); Lateral (Disc displaced lateral to lateral pole of condyle); Medial (Disc displaced medial to medial pole of condyle), Posterior (Disc displaced posterior to 12 o'clock position on top of condyle) and undetermined (disc not visualized) displacements. Classification criteria of the functional disc position in the open mouth Katzberg et al.¹⁰ With OM, it was classified as interposed between condyle and articular tubercle, disc displacement with reduction (DDWR), and disc displacement with no reduction (DDWNR). Classification criteria from Tasaki et al.⁹ and Katzberg et al.¹⁰ The position of the articular disc was classified as superior (normal) when it appeared to be located in the central portion of the mandibular condyle. A medial or lateral classification was determined when the disc was diagnosed in a medial or lateral pole of the condyle, as seen in a parasagittal plane tangent to the centre of the condyle.

the relative frequency of agreement observed in relation to the total TMJ number was used to verify consensus between O1 and O2 evaluations.

The sample was described as mean, standard deviation, minimum and maximum values for numerical variables and absolute and relative frequencies for categorical variables. The comparison of the groups of type of malocclusion was carried out with a Welch corrected ANOVA model or Kruskal-Wallis test for numerical quantities and Fisher's exact test or chi-square test for categorical variables. Pairwise comparison of groups was assessed using Games-Howell method, Steel-Dwass-Critchlow-Fligner method or a series of Holm corrected chi-square tests where applicable. Disc position and shape were measured on each side and a log-linear model for contingency tables without the triple interaction was fit to evaluate whether their relationship with the type of malocclusion was side-dependent. When this was not the case, the association between those variables was measured with the Cochran-Mantel-Haenszel (CMH) test. The association of disc position and shape with AO-BO was evaluated with a linear mixed model and with Ricketts' VERT using both a log-linear model with no triple interaction and CMH test. Pearson's chi-squared test was used to associate disc position in CM, OM and disc shape with the molar relationship side (Class I or Class III) in the Class III group subdivision.

Residual normality from the linear models was verified by inspecting the QQ plots, whereas homoscedasticity was assessed with Levene's test. All analyses were conducted on statistical package R 4.1.2 (R Core Team, 2021). All conclusions obtained through inferential analysis considered a 5% statistical significance level ($p \leq .05$).

3 | RESULTS

The relationship between the type of malocclusion and disc position in CM was selected to determine the sample size a posteriori. The observed effect size in the present study was Cohen's $w = 0.37$, and in order to detect it in a chi-square test with type I error of 5% and power of 80%, a sample size of 100 subjects would be sufficient. There was no statistically significant difference between the groups of individuals with and without alteration in the position and shape of the disc, in the right and left TMJs, in relation to the CVMS.¹⁷

The comparison of evaluations made by O1 (O1a×O1b), (O1b×O2) – *t* test, and the agreement between intra-observer (O1a×O1b) and inter-observer (O1b×O2), by ICC, showed that there was no significant difference in the cephalometric measurements and, respectively, presented excellent reliability.

In the calculations of the technical error of measurement, in the intra-observer and inter-observer analysis, the values of rTEM remained in the acceptable range for the facial axis angle (0.30%), facial depth angle (0.30%), lower facial height angle (0.81%) and for facial axis angle (0.35%), facial depth angle (0.37%), mandibular plane angle (1.07%), lower facial height angle (0.40%) and mandibular arc angle (0.79%), respectively. In the intra-rater and inter-rater analysis, the rTEM values for Ao-Bo (4.97%), mandibular plane angle (1.43%),

mandibular arc angle (1.26%) and Ao-Bo (4.79%), respectively, were above acceptable values.

The RC for each cephalometric measurement (intra-observer and inter-observer) presented values above 0.95, suggesting satisfactory reliability.

The AO-BO showed significant differences between the three groups. Ricketts' VERT differed only in the normal occlusion group (Table 1).

In the Class III group, the position of the articular disc was normal in 46 of the 66 TMJs (69.6%) with CM and interposed between the condyle and the articular tubercle in the OM position.

In 20 TMJs (30.3%), the discs were displaced with CM and presented a reduction in the OM position. In the Class III subdivision group, 79 of the 90 TMJs (87.7%) had normal disc position with CM and were interposed with OM. In 11 TMJs (12.2%), the discs were displaced in CM, showing a reduction in the OM position.

Biconcave discs were found in 59 TMJs (89.3%) and non-biconcave discs in 7 TMJs (10.6%) in the Class III group. In the Class III subdivision malocclusion group, 88 TMJs (97.7%) were observed with biconcave disc shape and 2 TMJs (2.2%) with undetermined shape.

The classification of the position and shape of the disc with CM and OM with the distribution of malocclusions and normal occlusion is presented in Table 2. Disc position with CM and OM in patients with normal occlusion is different from the groups with malocclusions. Regarding the shape of the articular disc, the Class III subdivision malocclusion group is probably different from the other groups ($p = .020$) (Table 2).

There was no association between AO-BO and facial pattern with position (CM, $p = .781/p = 1.000$; and OM, $p = 1.000/p = .698$) and disc shape (CM, $p = .532/p = .900$) within each group, respectively (Tables 3 and 4).

There was no association between disc position in CM ($p = .985$), OM ($p = .749$) and disc shape ($p = 1.000$) with the molar relationship side (Class I or Class III) in the Class III group subdivision.

The intra-observer and inter-observer agreements for disc position (CM and OM) and disc shape (CM) presented the following: 0.656 [0.514, 0.798] $p < .001$ (intra-observer disc position CM); 0.643 [0.465, 0.821] $p < .001$ (intra-observer disc position OM); 0.583 [0.318, 0.847] $p < .001$ (intra-observer disc shape CM); 0.874 [0.816, 0.932] $p < .001$ (inter-observer disc position CM); 0.777 [0.643, 0.911] $p < .001$ (inter-observer disc position OM); 0.235 [0.000, 0.489] $p = .399$ (inter-observer disc shape CM).

4 | DISCUSSION

The literature presents studies on the position and shape of the TMJ articular disc assessed by MRIs, in Class II malocclusions^{11,25} and children with functional unilateral crossbite.^{26,27} The comparisons of Class III and Class III subdivision malocclusions with the sagittal and vertical skeletal relationships and the difference in the position and shape of the TMJ articular disc have been less studied.⁵

TABLE 1 Comparisons of AO-BO and Ricketts' VERT with the types of malocclusions and normal occlusion

AO-BO	N	Mean	SD		t	p-value
Class III	33	-8.02	2.29	Class III × Class III subdivision	7676	<.001***
Class III subdivision	45	-5.71	2.38	Class III × Normal	13 189	<.001***
Normal	27	-0.65	1.51	Class III subdivision × Normal	13 403	<.001***

Ricketts' VERT	Brachyfacial		Dolichofacial		Mesofacial		p-value
	N	%	N	%	N	%	
Class III	20	60.6	6	18.1	7	21.2	Class III × Class III subdivision .592 NS
Class III subdivision	22	48.8	11	24.4	12	26.6	Class III × Normal .014*
Normal	7	25.9	3	11.1	17	62.9	Class III subdivision × Normal .021*

Note: Jacobson (AO-BO)²⁰; Kruskal-Wallis test. Ricketts' VERT²¹; Chi-square test.

Abbreviation: NS, not significant.

* $p \leq .05$; *** $p < .001$.

Displacement of the articular disc is relatively common in asymptomatic children.^{12,23} Although there were no clinically detected disc displacement situations with and without reduction (TMJ palpation in dynamics), with the completely asymptomatic studied sample, the MRIs showed 30.3% of disc displacement in the Class III group and 12.2% in Class III subdivision, which is considered an internal derangement.²⁸ Questions may arise, such as the importance of knowing the status of TMJs in patients at an early stage. Investigations have already demonstrated the possible relationship of asymmetric mandibular growth in patients with articular disc displacement.²⁹ However, a systematic review and meta-analysis¹⁶ suggest that longitudinal studies should be performed to confirm this possible relationship.

In the present study, all patients were in the CVMSI and CVMSII stages; in the pre-peak phase of pubertal growth, the Class III group (AO-BO-8.02 mm) had the greatest sagittal discrepancy, followed by the Class III subdivision (-5.71 mm) and normal occlusion (-0.65 mm) groups, in agreement with a previous research³⁰ that investigated the ANB variable. As for Ricketts' VERT, normal occlusion differed from groups with malocclusions, with a higher percentage (62.9%) of patients with mesofacial patterns (Table 1), not corroborating a previous study which found the highest percentage of hypodivergent patients.³⁰

There was no significant difference in Ricketts' VERT between Class III and Class III subdivision malocclusions ($p = .592$); as in both groups, the brachyfacial pattern was more prevalent (60.6% and 48.8%, respectively) (Table 1). A previous investigation comparing normal and malocclusions found a neutral standard for the Class III group.³¹ Significant differences between the craniofacial patterns of children with normal occlusion and Class III malocclusion were found in another study.³¹

Several studies have associated disc position and shape with malocclusions, although investigations with Class III and Class III subdivision malocclusions were not found in the literature. In the present study, the results showed that in 30.3% and 12.2% of the

TMJs the articular disc was displaced in Class III and Class III subdivision malocclusions, respectively. In agreement with our results, an investigation found joints (17%) with disc displacement in a sample of asymptomatic volunteers with chronological ages between 6 to 12 years,²³ although with different methodology from the present study.

Likewise, another study analysed the prevalence of disc displacement through MRI in 51 children and adolescents aged 8 to 15 years with malocclusions and reported a prevalence of disc displacement of 11.8%, although without describing the type of malocclusion.³²

Disc displacement may be associated with changes in facial morphology or malocclusion,^{7,12} as evidenced by a study with a sample of 923 children aged between 7 and 12 years. Significant sign associations were found, and TMD was associated with posterior cross-bite, open bite, Class II and III malocclusions, and maxillary overjet. Another study³³ found significant associations between the relationship between the Class III cusp and TMD.

In the present study, the most prevalent displacement was anterior disc displacement (ADD), in 12 TMJs (60.0%) and 7 TMJs (63.6%), followed by anteromedial disc displacement (AMDD) in 8 TMJs (40.0%) and 2 TMJs (18.18%) in Class III groups and Class III subdivision, respectively. In the Class III group subdivision 2, TMJs (18.1%) had anterolateral disc displacement (ALDD), unlike the results of a previous study.³² Other authors investigating a sample of pre-orthodontic adolescents aged 10 to 17 years reported that AMDD occurs more commonly than ALDD, corroborating the results of this study.¹²

There was no significant difference in the position and shape of the disc, in the Class III subdivision, when comparing the sides of the molar relationship of Class I and Class III, with CM and OM. In the present study, only one patient with Class III subdivision malocclusion presented unilateral disc displacement, condition which could be associated with alteration of skeletal symmetry.³⁴ However, the skeletal morphologies associated with TMJ disc displacement are not significantly different between symptomatic



TABLE 2 Distributions of disc position and shape with types of malocclusions and normal occlusion

Group	Articular disc position (CM)						Articular disc position (OM)						Articular disc shape								
	NL		ADD		ALDD		AMDD		DDWR		I		B		NB		U				
	N	%	N	%	N	%	N	%	N	%	N	%	Side	N	%	N	%	N	%		
Class III	Left	23	69.7	6	18.1	0	0.0	4	12.1	Left	10	30.3	23	69.7	Left	30	90.9	3	9.0	0	0.0
	Right	23	69.7	6	18.1	0	0.0	4	12.1	Right	10	30.3	23	67.7	Right	29	87.8	4	12.1	0	0.0
Class III sub	Left	40	88.8	3	6.6	1	2.2	1	2.2	Left	5	11.1	40	88.8	Left	44	97.7	0	0.0	1	2.2
	Right	39	86.6	4	8.8	1	2.2	1	2.2	Right	6	13.3	39	86.6	Right	44	97.7	0	0.0	1	2.2
Normal	Left	27	100.0	0	0.0	0	0.0	0	0.0	Left	0	0.0	27	100.0	Left	25	92.5	2	7.4	0	0.0
	Right	27	100.0	0	0.0	0	0.0	0	0.0	Right	0	0.0	27	100.0	Right	25	92.5	2	7.4	0	0.0
Log-linear model (triple interaction)		Statistic	0.093	gl	6	Valour-p	1.000 NS	Statistic	0.061	gl	2	Valour-p	.970 NS	Statistic	0.060	gl	4	Valour-p	1.000 NS		
Cochran-Mantel-Haenszel (CMH) test		Statistic	28148	gl	6	Valour-p	<.001**	Statistic	22272	gl	2	Valour-p	<.001***	Statistic	11685	gl	4	Valour-p	.020*		

Note: A log-linear model was fit and triple interaction tested to assess whether the relationship that the class III, class III subdivision and normal occlusion groups have with the position (CM and OM) and shape of the disc depends on the right or left side. In this case, there was no evidence of triple interaction, that is, the groups studied in relation to position (CM-p=1.000 and OM-p=0.970) and disc shape (p=1.000) are independent on the right and left side. Then, the Cochran-Mantel-Haenszel (CMH) test was applied, and it was observed that the position (CM-p<0.001 and OM-p<0.001) and shape of the articular disc (p=0.020) depend on the studied groups. As there is no method to compare groups two by two, these conclusions were drawn from the descriptive analysis.

Abbreviation: NL, normal; ADD, anterior disc displacement; ALDD, anterolateral disc displacement; AMDD, anteromedial disc displacement; DDWR, disc displacement with reduction; I, interposed; B, biconcave; NB, nonbiconcave; U, undetermined; NS, not significant.

* $p < .05$; ** $p < .01$; *** $p < .001$.

TABLE 3 AO-BO related to disc position and shape

Variables	Articular disc position (CM)	Mean (AO-BO)	SD	Articular disc position (OM)	Mean (AO-BO)	SD	Articular disc shape	Mean (AO-BO)	SD
Class III	NL	-8.22	2.44	DDWR	-7.55	1.81	B	-8.01	2.40
	ADD	-7.17	1.59	I	-8.22	2.44	NB	-8.07	0.67
	AMDD	-8.12	2.08						
Class III subdivision	NL	-5.72	2.40	DDWR	-5.64	2.16	B	-5.75	2.37
	ADD	-6.57	2.07	I	-5.72	2.40	U	-4.00	0.00
	ALDD	-5.00	0.00						
Normal	AMDD	-3.00	0.00						
	NL	-0.65	1.49	I	-0.65	1.49	B	-0.62	1.52
							NB	-1.00	1.15
Chi-sq	df	Pr(>Chi-sq)	Chi-sq	df	Pr(>Chi-sq)	Chi-sq	df	Pr(>Chi-sq)	
Disc position (CM)	3	0.781 NS	Disc position (OM) 0	1	1.000 NS	Disc shape	2	0.532 NS	
Group	2	<.001***	Group	2	<.001***	Group	2	<.001***	

Note: A linear mixed model was fit to verify whether the AO-BO in the studied groups (Class III, Class III subdivision and normal occlusion) is different depending on the position (CM and OM) and shape of the articular disc. There was no evidence of difference in the position (CM- $p = .781$ e OM- $p = 1.000$) and form of the articular disc ($p = .532$). It was observed that the AO-BO is different in the three groups (Class III, Class III subdivision and normal occlusion, regardless of the position (CM and OM) and shape of the articular disc, $p < .001$).

Abbreviations: ADD, anterior disc displacement; ALDD, anterolateral disc displacement; AMDD, anteromedial disc displacement; B, biconcave; CM, closed mouth; DDWR, disc displacement with reduction; I, interposed; NB, non-biconcave; NL, normal; NS, not significant; OM open mouth; U, undetermined.

*** $p < .001$.



TABLE 4 Ricketts' VERT related to disc position and shape

Group	Ricketts' VERT	Disc position (CM)						Disc position (OM)						Disc shape					
		NL		ADD		ALDD		AMDD		DDWR		I		B		NB		U	
		N	%	N	%	N	%	N	%	N	%	N	%	N	%	N	%	N	%
Class III	Brachyfacial	26	65.0	8	20.0	0	0.0	6	15.0	14	35.0	26	65.0	37	92.5	3	7.5	0	0.0
	Dolichofacial	10	83.3	2	16.6	0	0.0	0	0.0	2	16.6	10	83.3	12	100.0	0	0.0	0	0.0
	Mesofacial	10	71.4	2	14.2	0	0.0	2	14.2	4	28.5	10	71.4	10	71.4	4	28.5	0	0.0
Class III subdivision	Brachyfacial	39	88.6	3	6.8	0	0.0	2	4.5	5	11.3	39	88.6	44	100.0	0	0.0	0	0.0
	Dolichofacial	18	81.8	2	9.0	2	9.0	0	0.0	4	18.1	18	81.8	22	100.0	0	0.0	0	0.0
	Mesofacial	22	91.6	2	8.3	0	0.0	0	0.0	2	8.3	22	91.6	22	91.6	0	0.0	2	8.3
Normal	Brachyfacial	14	100.0	0	0.0	0	0.0	0	0.0	0	0.0	14	100.0	12	85.7	2	14.2	0	0.0
	Dolichofacial	6	100.0	0	0.0	0	0.0	0	0.0	0	0.0	6	100.0	6	100.0	0	0.0	0	0.0
	Mesofacial	34	100.0	0	0.0	0	0.0	0	0.0	0	0.0	34	100.0	32	94.1	2	5.8	0	0.0
Log-linear model (triple interaction)		Statistic	1854	gl	12	Valour-p	1.000 NS	Statistic	2208	gl	4	Valour-p	.698 NS	Statistic	3493	gl	8	Valour-p	.900 NS
Cochran-Mantel-Haenszel (CMH) test		Statistic	9337	gl	6	Valour-p	.156 NS	Statistic	0.442	gl	2	Valour-p	.802 NS	Statistic	8819	gl	4	Valour-p	.066 NS

Note: A log-linear model was fit and triple interaction tested to assess whether the position and disc shape depend on the facial pattern or on the studied groups. As there is no evidence of triple interaction, the position (CM- $p = 1.000$; OM- $p = .698$) and disc shape ($p = .900$) do not depend on the facial pattern or on the studied groups (Class III, Class III subdivision and normal occlusion) and, if they depend on any variable, they will only depend on one of them, not on both simultaneously. When the Cochran-Mantel-Haenszel (CMH) test was applied, it was observed that the facial pattern (Ricketts' VERT) is not associated with the position (CM- $p = .156$; OM- $p = .802$) and shape of the disc ($p = .066$) regardless of the groups studied (Class III, Class III subdivision and normal occlusion).

Abbreviations: ADD, anterior disc displacement; ALDD, anterolateral disc displacement; AMDD, anteromedial disc displacement; B, biconcave; DDWR, disc displacement with reduction; I, interposed; NB, non-biconcave; NL, normal; NS, not significant; U, undetermined.



and asymptomatic patients, and their clinical importance might be questioned.³⁵ Likewise, longitudinal investigation in adolescents has not found evidence of TMJ disc abnormality as an associated significant factor with mandibular dimensional changes.³⁶ Longitudinal studies with greater certainty of evidence should be conducted.¹⁶

The articular disc is normally biconcave; therefore, changes in disc shape are attributed to internal TMJ disorders, and a disc that has lost its normal shape is more likely to be dislocated.²³ In the group with normal occlusion, no ADD was observed, and in 4 TMJs (7.4%), they presented the non-biconcave form. In 11 TMJs that presented ADD in Class III subdivision malocclusions, 100% of the TMJs presented the biconcave shape of the articular disc. In Class III malocclusions, in 20 TMJs with disc displacement, 13 TMJs (65.0%) presented the biconcave form and 7 TMJs (35.0%) the non-biconcave form, corroborating a study that evaluated TMJs with MRI in children with functional unilateral posterior crossbite, which reported that 56 out of 60 TMJs (93.3%) had biconcave discs. Although in this study 20% of TMJs had disc displacement, this event is commonly associated with changes in their morphology.²⁶

In the present study, evaluating the shape of the disc, the Class III subdivision patients differed from the other two groups (Table 2). In a previous study,²⁷ the shape of the articular disc was analysed in two groups, a functional unilateral crossbite group and 1 control group. The authors found that in 24 out of 30 TMJs, (80.0%) the disc was biconcave, whereas in the control group, which included individuals without malocclusions, 26 out of 32 TMJs (81.3%) had a biconcave shape, suggesting that disc displacement may involve other factors.

In the present study, no differences were found within each group between the AO-BO and Ricketts' VERT variables and the position and shape of the articular disc in patients with Class III and Class III subdivision malocclusion (Tables 3 and 4). Between the malocclusions and normal occlusion groups, the 3 groups are different in the sagittal relationship of the bone bases (AO-BO) and the 2 groups of malocclusions are the same, but different in relation to the normal occlusion group with relationship to Ricketts' VERT. Between the groups, important differences were found in the position of the articular disc. Some studies have previously reported differences in growing patients with different malocclusions, demonstrating a relationship between TMD and Class III malocclusion, with the influence of the vertical mandibular growth pattern being more expressive.³⁷ Conversely, the concept of biological plausibility is not satisfied because the cause-effect relationship is not consistent with the current knowledge of the mechanisms of the disease. It can be concluded that occlusion is currently declining in importance and is now considered a cofactor. Other aetiological factors, such as trauma, parafunctional behaviour, psychosocial disorders, gender, genetics and centrally mediated mechanisms, are considered more important.³⁸

According to the sagittal relationship of the mandible, the skeletal characteristics associated with the displacement of the TMJ disc are represented differently. Individuals with a Class III skeletal

pattern would have less capacity to resist the functional stress produced by the displacement of the TMJ disc than those with Class I skeletal pattern.³⁹ A retrospective study of adult patients has shown that the severity of TMJ disc displacement increases as the sagittal skeletal classification changes from Class III to Class II deformities, and the vertical skeletal classification changes from hypodivergent to hyperdivergent deformities.⁴⁰

The main limitations of this study were the 2D sequences of the MRIs and the difficulty to discuss the results, mainly due to the lack of investigations in patients in this age group associated with Class III malocclusion, which evaluated the TMJs using MRIs.

5 | CONCLUSIONS

The null hypothesis (1) was rejected. The longitudinal follow-up of this sample becomes relevant as the two groups with malocclusion in the pre-peak phase of pubertal growth showed differences in the prevalence of displacement and form of the articular disc, with no association with their vertical facial characteristics.

AUTHOR CONTRIBUTIONS

Daniella Torres Tagawa involved in conceptualization, methodology, formal analysis, investigation, original draft and visualization. Alexandre de Albuquerque Franco involved in resources. Andrea Puchnick involved in formal analysis. Angela Maria Borri Wolosker involved in analysis and interpretation of data for the work and validation. Bruna Maluza Florez involved in data curation. Gladys Cristina Dominguez involved in writing-review. Helio Kiitiro Yamashita involved in substantial contributions to the conception or design of the work, investigation and visualization. Lucia Helena Soares Cevidanes involved in writing – review & editing. Luís Antônio de Arruda Aïdar involved in methodology, project administration and supervision. Henrique Carrete Junior involved in conceptualization, methodology and writing – original draft.

ACKNOWLEDGEMENTS

The authors thank Dr. Ricardo Leite Hayden, Dr. Luiz Antonio da Silva, Dr. Erico Paulo Heilbrun, Dr. Emilio Carlos Zanatta and the radiological technician Milena Aparecida Correia Silva for the opportunity and support in the execution of MRI.

CONFLICT OF INTEREST

The authors have no conflict of interest to disclose.

DATA AVAILABILITY STATEMENT

The data that support the findings of this study are available from the corresponding author upon reasonable request.

ORCID

Daniella Torres Tagawa  <https://orcid.org/0000-0002-5420-7344>

Alexandre de Albuquerque Franco  <https://orcid.org/0000-0002-6383-6513>



Andrea Puchnick  <https://orcid.org/0000-0002-7234-7121>
 Angela Maria Borri Wolosker  <https://orcid.org/0000-0002-2049-818X>
 Bruna Maluza Florez  <https://orcid.org/0000-0001-7604-9431>
 Gladys Cristina Dominguez  <https://orcid.org/0000-0002-8221-4912>
 Helio Kiitiro Yamashita  <https://orcid.org/0000-0002-1307-0687>
 Lucia Helena Soares Cevidanes  <https://orcid.org/0000-0001-9786-2253>
 Luis Antonio de Arruda Aida  <https://orcid.org/0000-0001-5930-7777>
 Henrique Carrete Junior  <https://orcid.org/0000-0003-2972-163X>

REFERENCES

- Ngan P. Early timely treatment of class III malocclusion. *Semin Orthod*. 2005;11(3):140-145.
- Da Silva CG, Pachêco-Pereira C, Porporatti AL, et al. Prevalence of clinical signs of intra-articular temporomandibular disorders in children and adolescents: a systematic review and meta-analysis. *J Am Dent Assoc*. 2016;147(1):10-18.
- Christidis N, Lindström Ndanshau E, Sandberg A, Tsilingaridis G. Prevalence and treatment strategies regarding temporomandibular disorders in children and adolescents – a systematic review. *J Oral Rehabil*. 2019;46(3):291-301.
- Benedicto EN, Kairalla SA, Kaieda AK, Miranda S, Torres FC, Paranhos L. Determinação do padrão esquelético vertical da face. *Rev Bras Cir Craniomaxilofac*. 2011;14(1):44-49.
- Hwang CJ, Sung SJ, Kim SJ. Lateral cephalometric characteristics of malocclusion patients with temporomandibular joint disorder symptoms. *Am J Orthod Dentofacial Orthop*. 2006;129(4):497-503.
- Kobayashi T, Honma K, Izumi K, Hayashi T, Shingaki S, Nakajima T. Temporomandibular joint symptoms and disc displacement in patients with mandibular prognathism. *Br J Oral Maxillofac Surg*. 1999;37(6):455-458.
- Muto T, Kawakami J, Kanazawa M, et al. Relationship between disc displacement and morphologic features of skeletal class III malocclusion. *Int J Adult Orthodon Orthognath Surg*. 1998;13(2):145-151.
- Yang Z, Wang M, Ma Y, et al. Magnetic resonance imaging (MRI) evaluation for anterior disc displacement of the temporomandibular joint. *Med Sci Monit*. 2017;23:712-718.
- Tasaki MM, Westesson PL, Isberg AM, Ren YF, Tallents RH. Classification and prevalence of temporomandibular joint disk displacement in patients and symptom-free volunteers. *Am J Orthod Dentofacial Orthop*. 1996;109(3):249-262.
- Katzberg RW, Westesson PL, Tallents RH, Drake CM. Anatomic disorders of the temporomandibular joint disk in asymptomatic subjects. *J Oral Maxillofac Surg*. 1996;54(2):147-153.
- Franco AA, Yamashita HK, Lederman HM, Cevidanes LH, Proffit WR, Vigorito JW. Fränkel appliance therapy and the temporomandibular disc: a prospective magnetic resonance imaging study. *Am J Orthod Dentofacial Orthop*. 2002;121(5):447-457.
- Nebbe B, Major PW. Prevalence of TMJ disc displacement in a pre-orthodontic adolescent sample. *Angle Orthod*. 2000;70(6):454-463.
- Flores-Mir C, Nebbe B, Heo G, Major PW. Longitudinal study of temporomandibular joint disc status and craniofacial growth. *Am J Orthod Dentofacial Orthop*. 2006;130(3):324-330.
- Zurfluh MA, Kloukos D, Patcas R, Eliades T. Effect of chin-cup treatment on the temporomandibular joint: a systematic review. *Eur J Orthod*. 2015;37(3):314-324.
- Hall HD. The correct operation for TMJ disc perforation. *J Oral Maxillofac Surg*. 1995;53(3):351.
- Marques FBC, de Lima LS, Oliveira PLE, et al. Are temporomandibular disorders associated with facial asymmetry? A systematic review and meta-analysis. *Orthod Craniofac Res*. 2021;24(1):1-16.
- Baccetti T, Franchi L, McNamara JA Jr. An improved version of the cervical vertebral maturation (CVM) method for the assessment of mandibular growth. *Angle Orthod*. 2002;72(4):316-323.
- Cevidanes LHS, Franco AA, Scanavini MA, Vigorito JW, Enlow DH, Proffit WR. Clinical outcomes of Fränkel appliance therapy assessed with a counterpart analysis. *Am J Orthod Dentofacial Orthop*. 2003;123(4):379-387.
- Dawson PE, Cranham JC. The complete dentist manual: the essential guide to being a complete care. In: Hess L, ed. *Complete Dentists Record Centric Relation Precisely*. Widiom Publishing Ilc Printed by CreateSpace; 2017:65-72.
- Jacobson A. The "Wits" appraisal of jaw disharmony. 1975. *Am J Orthod Dentofacial Orthop*. 2003;124(5):470-479.
- Ricketts RM. Perspectives in the clinical application of cephalometrics. The first fifty years. *Angle Orthod*. 1981;51(2):115-150.
- Pullinger AG, Hollender L. Variation in condyle-fossa relationship according to different method of evaluation tomograms. *Oral Surg Oral Med Oral Pathol*. 1986;62(6):719-727.
- Ribeiro RF, Tallents RH, Katzberg RW, et al. The prevalence of disc displacement in symptomatic and asymptomatic volunteers aged 6 to 25 years. *J Orofacial Pain*. 1997;11(1):37-47.
- Sim J, Wright CC. The kappa statistic in reliability studies: use, interpretation, and sample size requirements. *Phys Ther*. 2005;85(3):257-268.
- Aidar LAA, Dominguez GC, Abrahão M, Yamashita HK, Vigorito JW. Effects of Herbst appliance treatment on temporomandibular joint disc position and morphology: a prospective magnetic resonance imaging study. *Am J Orthod Dentofacial Orthop*. 2009;136(3):412-424.
- Masi M, Lederman HM, Yamashita HK, Aidar LAA. Temporomandibular joint evaluation with magnetic resonance imaging in children with functional unilateral posterior crossbite, treated with rapid maxillary expansion. *Am J Orthod Dentofacial Orthop*. 2009;136(2):207-217.
- Pellizoni SE, Salioni MA, Juliano Y, Guimaraes AS, Alonso LG. Temporomandibular joint disc position and configuration in children with functional unilateral posterior crossbite: a magnetic resonance imaging evaluation. *Am J Orthod Dentofacial Orthop*. 2006;129(6):785-793.
- Li DTS, Leung YY. Temporomandibular disorders: current concepts and controversies in diagnosis and management. *Diagnostics*. 2021;11(3):459.
- Kawakami M, Yamamoto K, Inoue M, Kawakami T, Fujimoto M, Kirita T. Morphological differences in the temporomandibular joints in asymmetrical prognathism patients. *Orthod Craniofac Res*. 2006;9(2):71-76.
- Pereira JCM, Lederman HM, Yamashita HK, Pereira DQ, Aidar LAA. Comparative cephalometric study of dentofacial patterns of individuals with normal occlusion and angle malocclusions. *Dental Press J Orthod*. 2011;16(5):62-73.
- Choi HJ, Kim JY, Yoo SE, Kwon JH, Park K. Cephalometric characteristics of Korean children with class III malocclusion in the deciduous dentition. *Angle Orthod*. 2010;80(1):86-90.
- Hans MG, Lieberman J, Goldberg J, Rozenzweig G, Bellon E. A comparison of clinical examination, history, and magnetic resonance imaging for identifying orthodontic patients with temporomandibular joint disorders. *Am J Orthod Dentofacial Orthop*. 1992;101(1):54-59.
- Alamoudi N. The correlation between occlusal characteristic and temporomandibular dysfunction in Saudi Arabian children. *J Clin Pediatr Dent*. 2000;24(3):229-236.
- Gidakou IK, Tallents RH, Stein S, Kyrkanides S, Moss ME. Comparison of skeletal and dental morphology in asymptomatic

- volunteers and symptomatic patients with unilateral disk displacement with reduction. *Angle Orthod.* 2004;74(2):212-219.
35. Naeije M, Te Veldhuis AH, Te Veldhuis EC, Visscher CM, Lobbezoo F. Disc displacement within the human temporomandibular joint: a systematic review of a 'noisy annoyance'. *J Oral Rehabil.* 2013;40(2):139-158.
 36. Flores-Mir C, Akbariamed L, Nebbe B, Heo G, Major PW. Longitudinal study on TMJ disk status and its effect on mandibular growth. *J Orthod.* 2007;34(3):194-199.
 37. Bastos LVW, Tesch RDS, Denardin OV. Cephalometric changes present in children and adolescents with TMJ disorders with different classes of malocclusions. *Rev Dental Press de Ortodontia e Ortopedia Fac.* 2008;13(2):40-48.
 38. Michelotti A, Iodice G. The role of orthodontics in temporomandibular disorders. *J Oral Rehabil.* 2010;37(6):411-429.
 39. Yang IH, Moon BS, Lee SP, Ahn SJ. Skeletal differences in patients with temporomandibular joint disc displacement according to sagittal jaw relationship. *J Oral Maxillofac Surg.* 2012;70(5):349-360.
 40. Jung WS, Kim H, Jeon DM, Mah SJ, Ahn SJ. Magnetic resonance imaging-verified temporomandibular joint disk displacement in relation to sagittal and vertical jaw deformities. *Int J Oral Maxillofac Surg.* 2013;42(9):1108-1115.

How to cite this article: Tagawa DT, Franco AdA, Puchnick A, et al. Temporomandibular joint articular disc position and shape in skeletal Class III. *Orthod Craniofac Res.* 2022;00:1-12. doi: [10.1111/ocr.12599](https://doi.org/10.1111/ocr.12599)